

PICTURES IN DIGESTIVE PATHOLOGY

Primary intestinal Hodgkin's lymphoma associated with Crohn's disease

Paulo Salgueiro¹, Paula Lago¹, Pedro Farrajota², Marisa Santos³ and Isabel Pedrito¹

¹Departments of Gastroenterology, ²Pathology and ³General Surgery. Hospital Santo António. Porto, Portugal

CASE REPORT

The authors present the case of a 37-years-old man with pancolic Crohn's disease (CD) diagnosed 20 years ago, characterized by a penetrating behavior with need for surgery (segmental colon resection) for a colovesical fistula. Due to a corticoid-dependent evolution, the patient has been in treatment with azathioprine for 8 years, with only partial clinical response, reason why he started infliximab (treatment continued for 3 years). An acute exacerbation prompted a colonoscopy that revealed severe inflammatory activity within the distal sigmoid and rectum with no changes in the remaining colonic and ileal mucosa (Fig. 1). Biopsies revealed infiltration of the mucosa by classic Hodgkin's lymphoma (Fig. 2), with positivity for Epstein-Barr virus (Fig. 3) and severe inflammatory activity. Computed tomography (Fig. 4) and bone marrow aspirate excluded extra intestinal lymphoproliferative disease (LD). After multidisciplinary consultation, the patient underwent total colectomy plus abdominoperineal resection of rectum (Fig. 5) with permanent ileostomy, the main indication was based on the lack of response to the medical therapy for CD. Since the resected specimen had no evidence of involvement of the isolated lymph nodes, it was decided not to start any adjunctive therapy.

Primary intestinal Hodgkin's lymphoma is very rare presenting an incidence of less than 0.5 % (1). Its association with CD is even rarer, with only sporadic cases described in literature (2).

There are still doubts whether the pathogenesis of the increased risk of LD in patients with CD correlates with the inflammatory disease activity or with the immunosuppressive treatment (3,4). The identification of Epstein-Barr virus infection in patients with Hodgkin's lymphoma is often reported in the described cases, suggesting that this agent might be implicated in the pathogenesis of the LD (5).

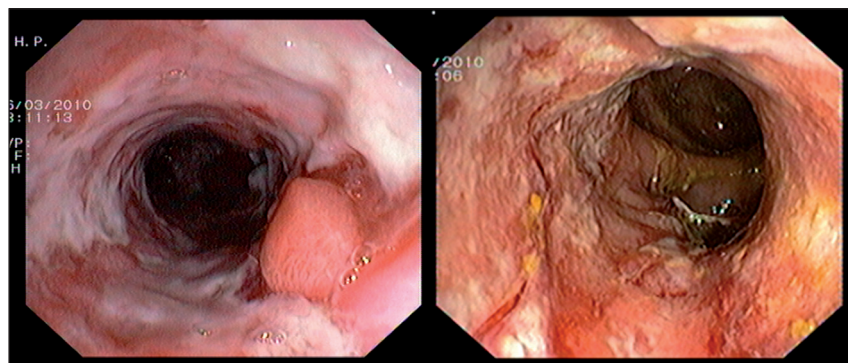


Fig. 1. Colonoscopy revealed multiple deep ulcers with purulent exudate deposits and areas suggestive of tissue necrosis.

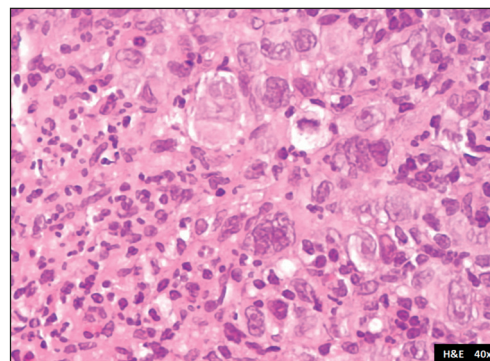


Fig. 2. Colonic mucosa samples revealing infiltration by atypical lymphocytes (Reed-Sternberg cells).

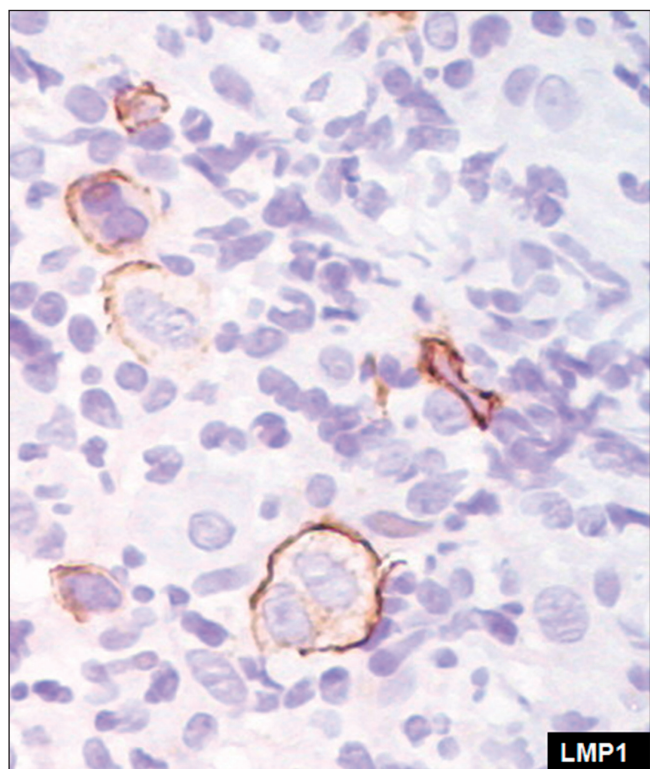


Fig. 3. Immunohistochemistry of the rectal samples showing Reed-Sternberg cells positive to latent membrane protein 1 (LMP1), meaning Hodgkin lymphoma related with Epstein-Barr virus infection.

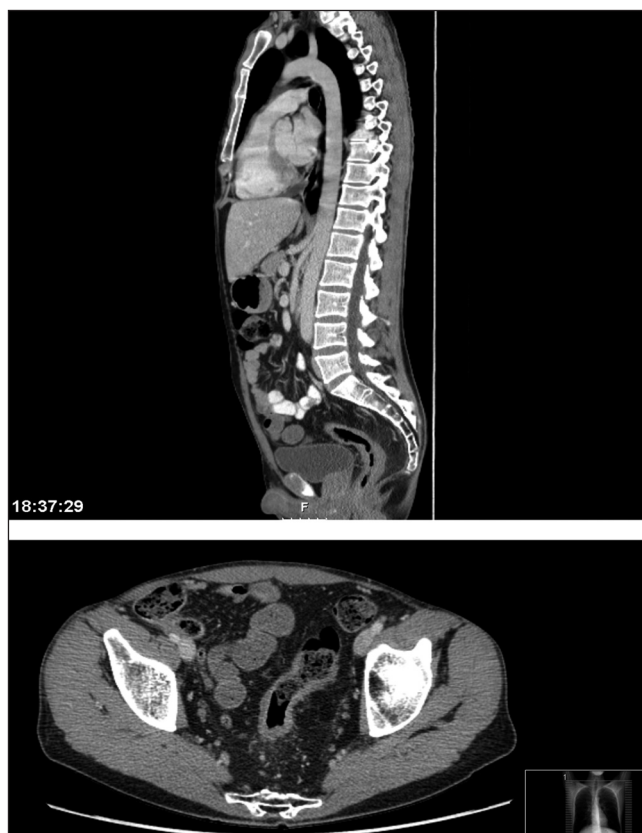


Fig. 4. Contrast-enhancement computed tomography where we can observe thickening of the rectum and sigmoid.

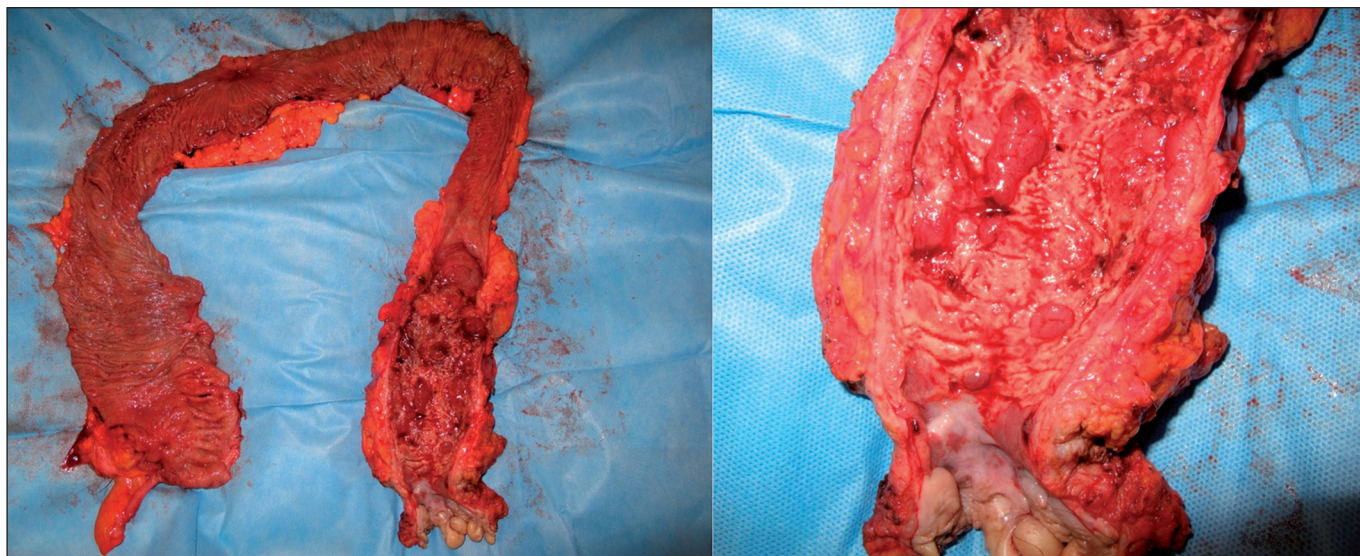


Fig. 5. Proctocolectomy specimen with macroscopic disease limited to the rectum and distal sigmoid.

REFERENCES

1. Askling J, Brandt L, Lapidus A, Karlén P, Björkholm M, Löfberg R, et al. Risk of haematopoietic cancer in patients with inflammatory bowel disease. *Gut* 2005;54:617-22.
2. Castrellon A, Feldman PA, Suarez M, Spector S, Chua L, Byrnes J. Crohn's disease complicated with primary gastrointestinal Hodgkin's lymphoma presenting with small bowel perforation. *J Gastrointest Liver Dis* 2009;18: 359-61.
3. Beaugerie L, Brousse N, Bouvier AM, Colombel JF, Lémann M, Cosnes J, et al. Lymphoproliferative disorders in patients receiving thiopurines for IBD: A prospective observational cohort study. *Lancet* 2009;374:1617-25.
4. Siegel CA, Marden SM, Persing SM, Larson RJ, Sands BE. Risk of lymphoma associated with combination anti-tumor necrosis factor and immunomodulator therapy for the treatment of Crohn's disease: A meta-analysis. *Clin Gastroenterol Hepatol* 2009;7:874-81.
5. Kumar S, Fend F, Quintanilla-Martinez L, Kingma DW, Sorbara L, Raffeld M, et al. Epstein-Barr virus-positive primary gastrointestinal Hodgkin's disease: Association with inflammatory bowel disease and immunosuppression. *Am J Surg Pathol* 2000;24:66-73.